

# Phototherapy with blue (415 nm) and red (660 nm) light in the treatment of acne vulgaris

P.PAPAGEORGIU, A.KATSAMBAS\* AND A.CHU

Unit of Dermatology, Imperial College of Science, Technology and Medicine, Hammersmith Hospital, DuCane Road, London W12 0NN, U.K.

\*Adreas Sygros Hospital, Athens, Greece

Accepted for publication 7 December 1999

## Summary

In this study we have evaluated the use of blue light (peak at 415 nm) and a mixed blue and red light (peaks at 415 and 660 nm) in the treatment of acne vulgaris. One hundred and seven patients with mild to moderate acne vulgaris were randomized into four treatment groups: blue light, mixed blue and red light, cool white light and 5% benzoyl peroxide cream. Subjects in the phototherapy groups used portable light sources and irradiation was carried out daily for 15 min. Comparative assessment between the three light sources was made in an observer-blinded fashion, but this could not be achieved for the use of benzoyl peroxide. Assessments were performed every 4 weeks. After 12 weeks of active treatment a mean improvement of 76% (95% confidence interval 66–87) in inflammatory lesions was achieved by the combined blue–red light phototherapy; this was significantly superior to that achieved by blue light (at weeks 4 and 8 but not week 12), benzoyl peroxide (at weeks 8 and 12) or white light (at each assessment). The final mean improvement in comedones by using blue–red light was 58% (95% confidence interval 45–71), again better than that achieved by the other active treatments used, although the differences did not reach significant levels. We have found that phototherapy with mixed blue–red light, probably by combining antibacterial and anti-inflammatory action, is an effective means of treating acne vulgaris of mild to moderate severity, with no significant short-term adverse effects.

*Key words:* acne, blue–red light, phototherapy

Acne vulgaris is one of the commonest skin conditions to affect humans, with 70% of adolescents developing acne. The mainstay of treatment of acne is the use of topical or systemic antibiotics. The rapid increase in the incidence of antibiotic resistance in the causative bacterium, *Propionibacterium acnes*, is causing great concern and there is a pressing need for effective, non-antibiotic treatments.

Acne often improves after exposure to sunlight or artificially produced solar radiation. *P. acnes* produces porphyrins<sup>1</sup> which absorb light energy at the near ultraviolet (UV) and blue light spectrum. Irradiation of *P. acnes* colonies with blue visible light leads to photoexcitation of bacterial porphyrins, singlet oxygen production and eventually bacterial destruction.<sup>2</sup> *In vivo* it has been shown that acne may be treated successfully with blue visible light phototherapy.

Red light may have anti-inflammatory properties by influencing the release of cytokines from macrophages or other cells but its exact mode of

action in the treatment of acne vulgaris is not yet fully understood.<sup>3</sup>

This study is the first to evaluate the use of a mixture of blue (415 nm) and red (660 nm) light and to compare this with blue light and benzoyl peroxide in the treatment of acne vulgaris.

## Materials and methods

The treatments tested were blue (415 nm) visible light and a mixture of blue and red (415 and 660 nm) visible light. Cool white light and 5% benzoyl peroxide cream were used as negative and positive controls, respectively.

Irradiation sources were fluorescent lamps in reflector fixtures, 4 × 15 W (type HF 885, Osram Sylvania, Brussels, Belgium). The red lamps had a symmetrical peak wavelength of 660 ± 10 nm. The blue lamps had an asymmetric peak of 415 nm +20/–15 nm. At a distance of 25 cm from the light

source, total irradiance was  $4.23 \text{ mW cm}^{-2}$  for blue light and  $2.67 \text{ mW cm}^{-2}$  for red light. Under these conditions the daily irradiation time for the phototherapy groups was 15 min so that a cumulative dose of  $320 \text{ J cm}^{-2}$  and  $202 \text{ J cm}^{-2}$  for blue light and red light, respectively, was achieved at the end of the treatment period.

The UV content of the blue tubes was 9% and of the mixed red and blue tubes was 7%, with the major part of the UV being UVA. No attempt was made to filter out this UV contamination as the output fell well within the Health and Safety Executive guidelines for occupational exposure of unprotected eyes and skin.

Patients with mild to moderate acne of either sex and age ranging from 14 to 50 years attending the dermatology out-patients clinic at the Hammersmith Hospital were asked to participate in this study with full written consent. All patients were otherwise healthy. The study was divided in two parts. First, the patients were recruited, a full medical and dermatological history was taken and a physical examination performed. Patients who were pregnant, on oral contraceptives, had taken oral antibiotics during the previous 2 weeks, and patients whose acne was assessed as very mild (with fewer than five inflammatory lesions) or severe (cystic) were all excluded from the study. Withdrawal criteria during the study included pregnancy, use of any acne treatment other than that issued, or any intake of oral antibiotics. The subjects were subsequently randomized into four treatment groups and were issued with a non-medicated soap to use for a 2-week wash-out period. After this period, each patient's acne was assessed by a spot count of both inflamed and non-inflamed lesions. Patients were exposed to one of the three light sources in a single blind fashion or were treated with 5% benzoyl peroxide cream (unable to be blinded) using a computerized randomization list. Written instructions on how to use each treatment were also issued. Patients were followed up every 4 weeks over a 12-week period. At each visit, a spot count and subject and investigator assessments of the severity of acne were made. Assessments were

made blind by two assessors. At the final visit, the patient and the investigator also assessed overall treatment response as 'worse' ( $\leq -10\%$ ), 'unchanged' ( $-9-9\%$ ), 'mild improvement' ( $10-39\%$ ), 'moderate improvement' ( $40-59\%$ ), 'marked improvement' ( $60-89\%$ ) or 'clearance' ( $\geq 90\%$ ).

### Statistics

A repeated measures analysis of variance was used to evaluate the significance of mean percentage improvements in spot counts within each treatment group between baseline and subsequent visits as well as between-group differences. Where pairs of comparisons were performed the resulting *P*-values had a Bonferroni correction applied to them to adjust for the number of comparisons made. Fisher's exact tests were used to compare treatments with respect to investigator and patient overall assessment, and frequency of side-effects.

### Results

One hundred and seven patients were randomized into four treatment groups, blue light, blue-red light, white light and benzoyl peroxide. The groups were of similar size and well matched at baseline with respect to age, sex, and duration and severity of acne (Table 1).

Looking at the percentage improvement in inflammatory spots, there was strong evidence of a difference between time points (over all treatment groups), with  $P < 0.001$ . There was also strong evidence of a difference between treatment groups (over all time points), with  $P < 0.001$  (Fig. 1).

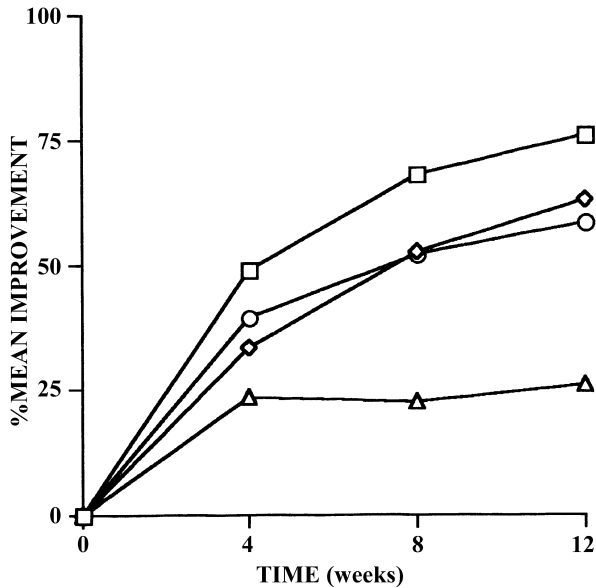
Table 2 looks at the differences for each time point separately between the blue-red group and each of the other three groups (difference in mean percentage improvements of inflammatory lesions and 95% confidence intervals for these differences). There were reasonably significant differences between the blue-red light and blue light groups at weeks 4 ( $P = 0.02$ ) and 8 ( $P = 0.02$ ), but the difference at the final visit

**Table 1.** Demographic data

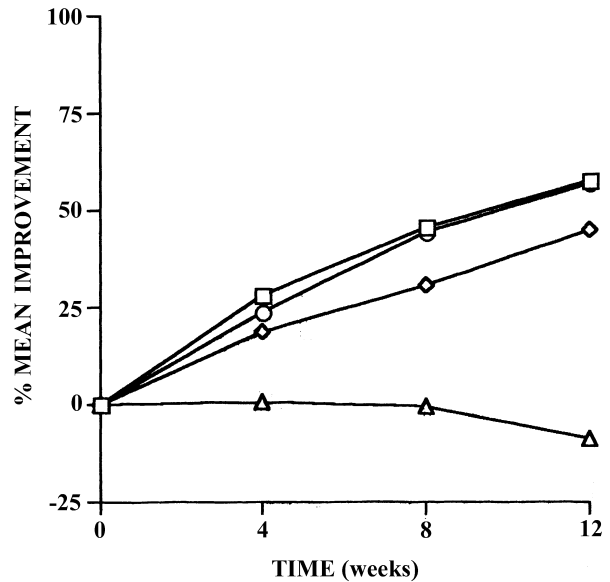
	Blue-red light	Blue light	Benzoyl peroxide	White light
No. of patients	30	27	25	25
Sex (m/f)	9/21	8/19	9/16	7/18
Mean age (years)	24.8	23.4	26.7	25.6
Inflammatory spots (mean, range)	30 (9-94)	48 (6-120)	30 (5-108)	39 (5-110)
Comedones (mean, range)	101 (16-322)	159 (27-286)	112 (26-376)	112 (11-428)

**Table 2.** Difference in mean percentage improvements in inflammatory lesions between treatments (95% confidence intervals)

	Blue-red vs. blue light	Blue-red light vs. benzoyl peroxide	Blue-red vs. white light
Week 4	15.6 (5.5-25.7)	9.6 (-0.4-19.7)	25.4 (15.2-35.6)
Week 8	15.6 (5.5-25.7)	15.7 (5.6-25.8)	45.1 (34.9-55.4)
Week 12	13.1 (3.0-23.1)	17.6 (7.5-27.6)	50.3 (40.1-60.5)



**Figure 1.** Inflammatory spot counts. □, Blue-red light; ◇, blue light; ○, benzoyl peroxide; △, white light.



**Figure 2.** Comedone counts. □, Blue-red light; ◇, blue light; ○, benzoyl peroxide; △, white light.

did not reach significant levels ( $P = 0.10$ ). The difference between the blue-red light and benzoyl peroxide was also significant in favour of blue-red light at weeks 8 ( $P = 0.02$ ) and 12 ( $P = 0.006$ ). Blue-red light was superior to the white light at all time points ( $P < 0.001$ ).

The percentage improvement in comedone count was analysed in exactly the same manner as above. Again, there was strong evidence of a difference between time points (over all treatment groups) with  $P < 0.001$ , and strong evidence of a difference between treatment groups (over all time points) with  $P < 0.001$  (Fig. 2).

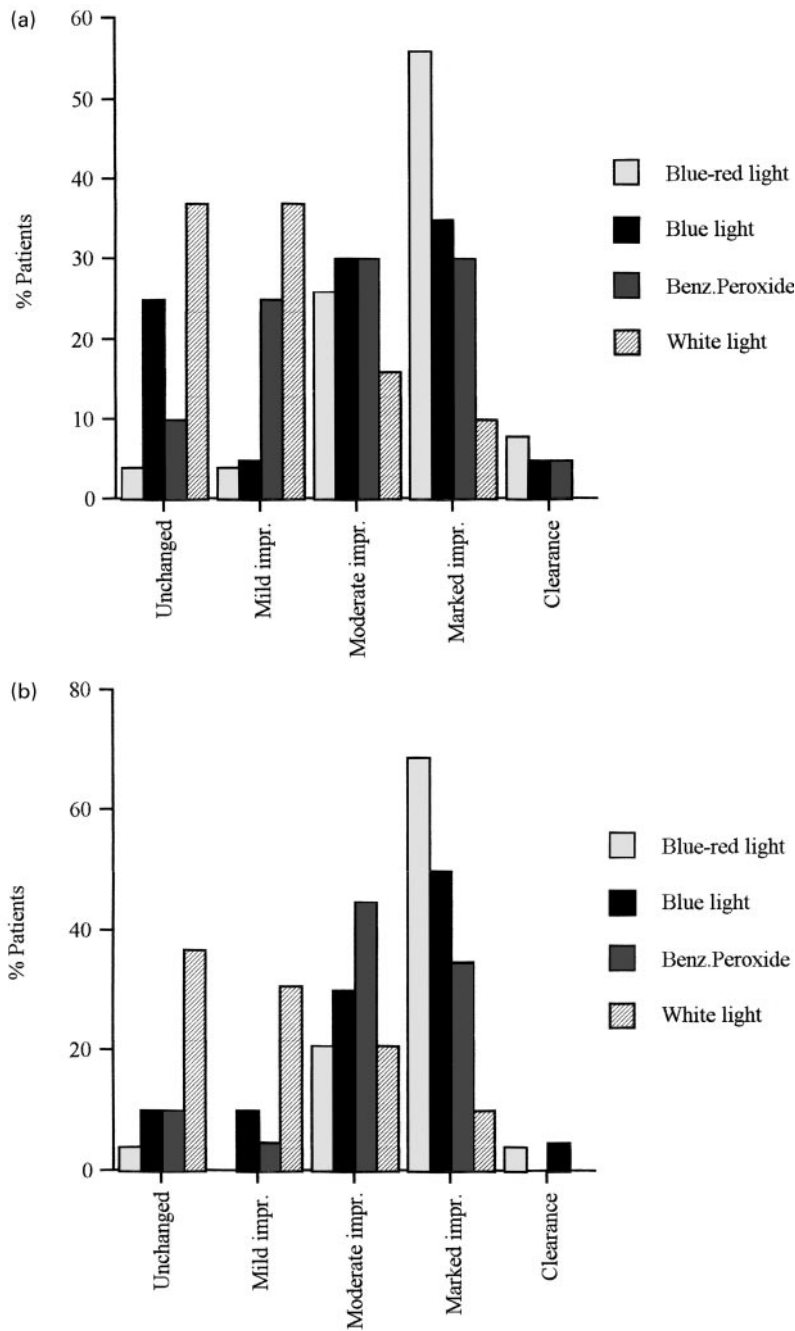
Differences in mean percentage improvements of comedonal lesions and 95% confidence intervals for these differences are presented in Table 3. There were

significant differences between the blue-red light and the white light groups at all time points ( $P < 0.001$ ). The improvement achieved by the blue-red light was superior to those of blue light and benzoyl peroxide but the differences did not reach levels of statistical significance. Investigators' and patients' overall assessments are presented in Figure 3a and 3b, respectively. Investigator and patient assessments were in favour of the blue-red light, with more patients achieving marked improvement or clearance than in any of the other treatment groups.

Adverse reactions are summarized in Table 4; during the 12-week period nine subjects experienced deterioration of their acne and discontinued their treatment. Five patients in the blue-red light, four in the blue light, four in the white light, and three in the benzoyl

**Table 3.** Difference in mean percentage improvements in comedones between treatments (95% confidence intervals)

	Blue-red vs. blue light	Blue-red light vs. benzoyl peroxide	Blue-red vs. white light
Week 4	9.5 (-0.8-19.8)	4.1 (-6.2-14.5)	27.3 (16.8-37.8)
Week 8	15.4 (5.1-25.8)	1.3 (-9.0-11.7)	46.4 (36.0-56.9)
Week 12	12.9 (2.5-23.2)	0.9 (-9.4-11.3)	66.5 (56.0-77.0)



**Figure 3.** (a) Investigators' overall assessments; (b) patients' overall assessments.

**Table 4.** Adverse effects. NS, not significant.

	Blue-red light	Blue light	Benzoyl peroxide	White light	P
Flare up of acne	2 (6.6%)	3 (11.1%)	2 (8%)	2 (8%)	NS
Dryness/itch	1 (3.3%)	3 (11.1%)	8 (32%)	2 (8%)	< 0.001
Facial rash	2 (6.6%)	1 (3.7%)	2 (8%)	0	NS
Headaches	1 (3.3%)	0	0	0	NS

peroxide group were voluntarily withdrawn before the end of the 12 weeks' treatment (NS). The main reason for this in the phototherapy groups was non-compliance in following the time-schedule on using the light boxes.

## Discussion

The pathogenesis of acne is poorly understood. It appears to be a multifactorial process involving high sebum excretion rate, microcomedone formation, sebum inspissation and inflammation. Propionibacteria in the follicular canal break down sebum triglycerides to free fatty acids and also produce chemoattractant cytokines for leucocytes. They seem to be important both in ductal occlusion and in induction of the inflammatory response and thus in the formation of comedones and inflammatory lesions.

Protoporphyrin IX is taken up by *P. acnes* in suspension via cell wall receptors and stored intracellularly.<sup>1</sup> As a result, when viewed in Wood light, acne follicles fluoresce coral red.<sup>4</sup>

*In vitro*, *P. acnes* has been inactivated by relatively small doses ( $D_{10} = 5 \text{ kJ m}^{-2}$ ) of broad band near-UV radiation; this phenomenon was found to be oxygen dependent.<sup>2,5</sup> The sensitivity was highest for the lowest wavelength used (320 nm), decreasing continuously towards longer wavelengths but had a secondary maximum in the blue region at 415 nm. The latter corresponds to the absorption maximum of the porphyrins produced by *P. acnes*, which are very likely to act as chromophores. Therefore, irradiation of *P. acnes* with light in the blue region (415 nm) could result in photodynamic stimulation of porphyrins stored in the bacteria, singlet oxygen production and bacterial killing.<sup>5</sup> Recently it has also been shown that irradiation of *P. acnes* with UVA and blue light, by affecting transmembrane proton influx, induces intracellular pH alterations and bacterial damage.<sup>6</sup>

It is well known that acne often improves clinically after exposure to sunlight or artificially produced UV radiation. In 1987 Meffert *et al.*<sup>7</sup> reported improvement of acne and seborrhoea on the face and back in male volunteers after 17 radiations with a cumulative dose of  $22 \text{ kJ cm}^{-2}$ , using halogen lamps that emit visible light. The degree of improvement was comparable with that observed with UVA. This effect is apparently attributed to photodynamic stimulation of porphyrins stored in *P. acnes* whereas UVA irradiation induces the production of superoxide anions, membrane damage and single strand breaks in DNA.<sup>2,5</sup>

Phototherapy of acne vulgaris with a blue light-emitting source, better adapted to the absorption spectrum of porphyrins, would result in a therapeutic response with a reduced irradiation dose and avoiding the theoretical risks of UV radiation. In a study by Meffert *et al.* in 1990,<sup>8</sup> both acne and seborrhoea improved markedly with a blue light-type high-pressure lamp after 10 irradiations, each for 10 min, and a cumulative light dose of  $325 \text{ J cm}^{-2}$ . In our study the mean improvement was 45% (95% confidence interval 32–59) in comedones and 63% (95% confidence interval 52–74) in inflammatory lesions using a cumulative blue light dose of  $320 \text{ J cm}^{-2}$ .

The use of red light in the treatment of acne has been less well explored. Biostimulation with low-level laser energy is a complex subject of ongoing investigation. In wound healing low-energy laser radiation has been found to have a stimulating effect on cells whereas high-energy radiation had an inhibitory effect.<sup>9</sup> Macrophages exposed to 660 nm low-level wavelengths release cytokines which stimulate fibroblast proliferation and the production of growth factors, thus influencing the inflammatory process, healing and wound repair.<sup>3,10,11</sup> It has also been shown that permeability of the cell membrane to calcium ions may be affected by lasers emitting red light.<sup>12</sup>

However, at least some of these biological effects can be achieved by exposure to non-coherent low-level red light.<sup>13</sup> Irradiation with low-level narrow band light (660 nm) has *in vitro* induced the release of growth factors by macrophages<sup>14</sup> and *in vivo* significantly improved postoperative open wounds.<sup>15</sup>

We found a final mean improvement of 76% (95% confidence interval 66–87) in inflammatory lesions using a combined blue-red light radiation which was significantly superior to those achieved by blue light or benzoyl peroxide. The final mean improvement in comedones was 58% (95% confidence interval 45–71). Again, the combined blue-red light phototherapy did better than the other treatments used but the difference did not reach significant levels.

Both the blue lamp and the red and blue lamps produced some UV radiation, constituting 9% of the output of the blue and 7% of the output of the red and blue. It is possible that the UV content of the tubes contributed to the clinical effect of the treatment but the UV content was low, mainly long wavelength UV, and the red/blue tubes had a clinical effect superior to that of the blue tubes, even though the blue tubes produced more UV. The

UV content of the lamp was low and did not constitute a risk to patients using the lamp.

We propose that blue light and red light may act synergistically in improving acne by combining antibacterial and anti-inflammatory action, rendering phototherapy with blue-red light an effective and safe treatment for acne vulgaris.

## References

- 1 Melo TB. Uptake of protoporphyrin and violet light photo-destruction of *Propionibacterium acnes*. *Z Naturforsch C* 1987; **42**: 123–8.
- 2 McGinley KJ, Webster GF, Leyden JJ. Facial follicular porphyrin fluorescence. Correlation with age and density of *Propionibacterium acnes*. *Br J Dermatol* 1980; **102**: 437–41.
- 3 Kjeldstad B. Photoinactivation of *Propionibacterium acnes* by near-ultraviolet light. *Z Naturforsch* 1984; **39**: 329–35.
- 4 Kjeldstad B, Johnsson A. An action spectrum for blue and near ultraviolet inactivation of *Propionibacterium acnes*; with emphasis on a possible porphyrin photosensitization. *Photochem Photobiol* 1986; **43**: 67–70.
- 5 Arakane K, Ryu A, Hayashi C *et al.* Singlet oxygen ( $^1\Delta_g$ ) generation from coproporphyrin in *Propionibacterium acnes* on irradiation. *Biochem Biophys Res Commun* 1996; **223**: 578–82.
- 6 Futsaether CM, Kjeldstad B, Johnsson A. Intracellular pH changes induced in *Propionibacterium acnes* by UVA radiation and blue light. *J Photochem Photobiol B* 1995; **31**: 125–31.
- 7 Meffert H, Scherf HP, Sönnichsen N. Behandlung von Akne vulgaris mit sichtbarem Licht. *Dermatol Monatsschr* 1987; **173**: 678–9.
- 8 Meffert H, Gaunitz K, Gutewort T, Amlong UJ. Acnetherapie mit sichtbarem Licht. *Dermatol Monatsschr* 1990; **176**: 597–603.
- 9 Mester E, Mester AF, Mester A. The biomedical effects of laser application. *Lasers Surg Med* 1985; **5**: 31–9.
- 10 Yu W, Naim JO, Lonzaface KJ. Effects of photostimulation on wound healing in diabetic mice. *Lasers Surg Med* 1997; **20**: 56–63.
- 11 Abergel RP, Lyons RE, Castel JC *et al.* Biostimulation of wound healing by lasers; experimental approaches in animal models and fibroblast cultures. *J Dermatol Surg Oncol* 1987; **13**: 127–33.
- 12 Breitbart H, Levinshal T, Cohen N *et al.* Changes in calcium transport in mammalian sperm mitochondria and plasma membranes irradiated at 633 nm (He-Ne laser). *J Photochem Photobiol B* 1996; **34**: 117–21.
- 13 Karu TI. Photobiological fundamentals of low-power laser therapy. *J Quantum Electron* 1987; **10**: 23.
- 14 Young S, Bolton P, Dyson M *et al.* Macrophage responsiveness to light therapy. *Lasers Surg Med* 1989; **9**: 497–505.
- 15 Iusim M, Kimchy J, Pillar T *et al.* Evaluation of the degree of effectiveness of Biobeam (low level narrow band light) on the treatment of skin ulcers and delayed post-operative wound healing. *Orthopedics* 1992; **15**: 1023–6.